

PATIENT

Guiness Jakusiak

SPECIES

Canine

BREED

Cavapoo

SEX

Male Neutered

AGE

14.6 years

WEIGHT

10lbs

INTERPRETED BY

Maggie Machen Lamy,
DVM, DACVIM
(Cardiology)

IMAGING PERFORMED BY

Sands Hill Mobile
Veterinary Ultrasound

HOSPITAL NAME

Whole Pet Vet

REFERRING VET

Dr. Rubendall

INVOICE

29503

DATE

3/9/23

PRESENTING CLINICAL SIGNS

History: Recent cough/breathing issue at home. X-rays suggestive of pulmonary congestion. Trouble recently with hypoglycemia-was on 3-4 units BID, now he is on Vetsulin 2 units BID. Heart murmur for 6-7 months has worsened. Hypertensive today BP Systolic-230mmHG. 3/9/23 -Enalapril 2.5 PO at noon today, Lasix 12.5mg at 11:30AM.
-Abnormal PE/Chem/CBC/UA Results: BG has been from 80-400 this last week.

RADIOGRAPHIC FINDINGS *NOTE: Images submitted for supplemental cardiac information only.
Mild cardiomegaly. No obvious evidence of CHF.

ECHOCARDIOGRAM FINDINGS

2D, m-mode, color flow and doppler imaging is available. Diffuse nodular thickening of mitral valve leaflets with mild prolapse into the left atrial lumen. Moderate eccentric mitral regurgitation with mild left atrial dilation. Normal MR velocity. Mild LV dilation with adequate myocardial function. The tricuspid valve appears thickened with mild to moderate tricuspid regurgitation. Velocity consistent with mild to moderate PAH. Mild right atrial and ventricular prominence. The pulmonic and aortic valves are normal in morphology and mobility. Normal pulmonic and aortic outflow velocities with laminar flow. No obvious aortic or pulmonic insufficiency. No pericardial or pleural effusion noted. No obvious cardiac masses.

CARDIAC CHART

CANINE CARDIAC PARAMETERS	MR VMAX (m/s)	TR VMAX (m/s)	LA/AO (Boon method)	LA/AO (Heart Base; Swe)	FS (%)	EF (%)	EPSS (cm)
NORMAL PARAMETER	4.5-5.5	<2.7	1.3	<1.6	28-40	40-100	<0.6
PATIENT	5.3	3.15	1.4	1.5	59	89	NM
CANINE CARDIAC PARAMETERS	HR (BPM)	AV VMAX (m/s)	PV MAX (m/s)	BODY WEIGHT (kg)	LA 2D short axis Base view (cm)	LVIDd Avg; 2D and m-mode short axis (cm)	LVIDs Avg; 2D and m-mode short axis (cm)
NORMAL PARAMETER	50-100	0.7-1.7	0.7-1.6	BELOW	BELOW	BELOW	BELOW
PATIENT	1160	1.0	0.74	4.5	1.9	3.2	1.3
*Normal chamber parameters expressed as a mean value (SD)				3	1.27 (5.3)	2.46 (2.46)	1.36 (5.5)
BODY WEIGHT DEPENDENT PARAMETERS				5	1.40 (4.5)	2.74 (5.2)	1.60 (4.7)
<i>*Note: All measurements based upon multi-modal images and methods. An average value is reported.</i>				10	1.50 (3.8)	3.27 (3.5)	2.06 (3.1)
				15	1.83 (2.0)	3.71 (2.4)	2.43 (2.1)
				20	2.02 (1.9)	4.14 (2.2)	2.80 (2.0)
				25	2.18 (2.4)	4.48 (2.9)	3.10 (2.5)
				30	2.33 (3.3)	4.83 (3.9)	3.39 (3.4)
				35	2.48 (4.3)	5.17 (5.0)	3.69 (4.5)
				40	2.62 (5.2)	5.48 (6.1)	3.96 (5.4)
				50	2.88 (7.1)	6.07 (8.3)	4.46 (7.4)

INTERPRETATION OF THE FINDINGS & FURTHER RECOMMENDATIONS

Chronic degenerative valve disease causing moderate mitral and mild to moderate tricuspid regurgitation. Lack of significant left atrial enlargement indicates the current risk for complication is low. The TR velocity and mild right heart changes are suggestive of mild to moderate PAH,



PATIENT

Guiness Jakusiak

which is suspected to be secondary to primary respiratory disease. No concurrent issues such as systolic dysfunction are noted in this study.

SPECIES

Canine

The underlying genesis of PAH is poorly understood in cases other than heartworm infestation, though it occurs with increased frequency in a variety of forms of chronic lung disease and in patients with idiopathic pulmonary fibrosis. If not performed, a heartworm antigen test is recommended. Given the history of a chronic cough, COPD/chronic bronchitis and collapsing trachea is the likely underlying cause. An acute increase in symptom with labored breathing is primary respiratory in origin, with a secondary exacerbating insult (infectious or inflammatory) suspected. It is important to note that the PAH does not cause the clinical signs; rather it develops secondary to airway disease/hypoxia.

BREED

Cavapoo

SEX

Male Neutered

Coverage with broad spectrum pulmonary antibiotic (fluoroquinolone) is recommended, with oxygen support and sedation if needed. If response to treatment is less than ideal, a Sildenafil trial can be safely instituted to assess response. No obvious indication for additional medications such as Pimobendan at this time. Diuretic therapy is not recommended, as decreasing blood volume can further decrease preload and worsen clinical signs in the absence of CHF.

AGE

14.6 years

Once stable, continued use of theophylline and/or taper course of anti-inflammatory steroids can also be beneficial in these cases, to treat exertional dyspnea or acute flare ups and decrease the inflammatory component as much as possible. PRN use of cough suppressants may also be beneficial. Unfortunately, the prognosis overall is guarded to poor with severe airway disease.

WEIGHT

10lbs

The reported blood pressure is elevated, and should be reassessed for persistence once the stressful event is stabilized, particularly given no reported clinical signs of severe hypertension (retinal changes, etc) or evidence of LVH on echo. Ideally obtain serial measurements in a controlled, low stress environment and continue until 3 consecutive readings plateau within 5mmHg of variability. If persistently >180mmHg despite a relatively calm demeanor, recommend institution of amlodipine to effect. Additionally if deemed accurate, screening for predisposing underlying causes of SHT is recommended (Cushings, PLN, adrenal tumor, etc), as primary disease is relatively uncommon and a rule out diagnosis.

INTERPRETED BY

Maggie Machen Lamy,
DVM, DACVIM
(Cardiology)

Omega fatty acid supplementation (anti-inflammatory) may be of some long-term benefit. Monitor for worsening of labored breathing, exercise intolerance or collapse episodes.

IMAGING PERFORMED BY

Sands Hill Mobile
Veterinary Ultrasound

PLAN

Recommend coverage with a pulmonary antibiotic (Enrofloxacin or similar). Discontinue Lasix/ACEI. Further hospitalization/airway treatment as needed. If persistent tachypnea, institute Sildenafil trial; 1-2mg/kg PO q8h for 1-2 weeks and assess for clinical improvement. Reassess BP for persistence; if indicated institute Amlodipine and screen for underlying causes.

HOSPITAL NAME

Whole Pet Vet

REFERRING VET

Dr. Rubendall

Recommend recheck echocardiogram in 6 months to reassess pulmonary pressures, sooner if any development of clinical signs.

INVOICE

29503

DATE

3/9/23



PATIENT

Guiness Jakusiak

SPECIES

Canine

BREED

Cavapoo

SEX

Male Neutered

AGE

14.6 years

WEIGHT

10lbs

INTERPRETED BY

Maggie Machen Lamy,
DVM, DACVIM
(Cardiology)

**IMAGING
PERFORMED BY**

Sands Hill Mobile
Veterinary Ultrasound

HOSPITAL NAME

Whole Pet Vet

REFERRING VET

Dr. Rubendall

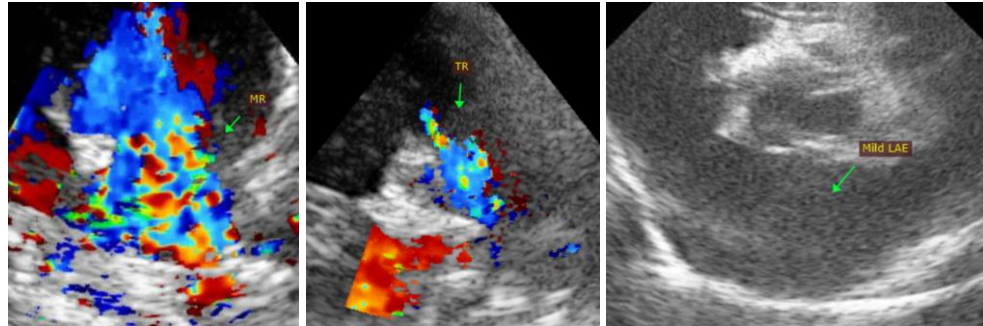
INVOICE

29503

DATE

3/9/23

IMAGES



The information and recommendations provided are based on the images presented by the referring veterinarian. No evaluation can be communicated regarding pathology that was not visible in the image/video clips provided.

Thank you for this referral. This report was generated using transcription software, and minor dictation errors may be present. If the clinical or image interpretation does not parallel your findings or if I can be of any further assistance, please contact me.

Maggie Machen Lamy, DVM
Diplomate of the American College of Veterinary Internal Medicine (Cardiology)
info@sonopath.com